



**PATIENT**

Jagger Gjormand

**SPECIES**

Canine

**BREED**

Mini Pinscher

**SEX**

Neutered Male

**AGE**

3

**WEIGHT**

Not Provided

**INTERPRETED BY**

Andrea Nicastrò DVM  
Diplomate ACVIM  
(Sm Animal Internal Med)

**IMAGING PERFORMED BY**

Andrea Nicastrò DVM  
Diplomate ACVIM  
(Sm Animal Internal Med)

**HOSPITAL NAME**

Dunes VC

**REFERRING VET**

Dr Danny Soileau

**INVOICE**

22680

**DATE**

3-13-26

**PRESENTING CLINICAL SIGNS**

Patient is asymptomatic. Not on any medication. February 2024 bloodwork: ALT 357. February 2026: ALT 880. ALP and GGT are normal. Tbili 0.5. CBC unremarkable.

**ULTRASONOGRAPHIC EXAMINATION OF THE ABDOMEN**

**Urinary System**

The urinary bladder wall is normal in thickness. The mucosal surface is smooth. The bladder is moderately distended. A small amount of suspended echogenic debris is observed within the lumen. No cystic calculi are observed. The region of the trigone and the proximal urethra, visible to a depth of 2.5-3.0 cm, are normal.

The prostate is normal in size (0.77 cm in width) and shape. Parenchyma is homogenous. The prostatic urethra appears normal without evidence of dilation or obstruction.

The left kidney is normal in size (4.42 cm in length) with a normal shape, architecture and smooth peripheral margins. There is a normal 1:3 cortex to medulla ratio with minimal loss of corticomedullary distinction. There is no evidence of pyelectasia, nephroliths, infarcts or hydronephrosis. Renal vasculature is normal.

The right kidney is normal in size (4.18 cm in length) with a normal shape, architecture and smooth peripheral margins. There is a normal 1:3 cortex to medulla ratio with minimal loss of corticomedullary distinction. There is no evidence of pyelectasia, nephroliths, infarcts or hydronephrosis. Renal vasculature is normal.

**Adrenal Glands**

The left adrenal gland is normal in size (0.43 cm at cranial pole) (0.46 cm at caudal pole) with a normal shape and homogenous parenchyma. The glandular echogenicity and detail are unremarkable. Capsule, cortex, and medullary definition are normal. The phrenicoabdominal vein and surrounding vasculature are normal.

The right adrenal gland is normal in size (0.68 cm at cranial pole) (0.44 cm at caudal pole) with a normal shape and homogenous parenchyma. The glandular echogenicity and detail are unremarkable. Capsule, cortex, and medullary definition are normal. The phrenicoabdominal vein and surrounding vasculature are normal.

**Spleen**

The spleen is normal in size (0.95 cm in width at the level of the hilus) with a normal capsular contour. There is appropriate echogenicity and echotexture. No focal lesions are observed. Splenic vasculature is normal.

**Liver**

The liver is subjectively normal in size with normal contours and structure. There is appropriate echogenicity and echotexture. No overt structural evidence of inflammatory, infiltrative, or regenerative pathology is evident. Vascular and biliary tracts are of normal volume with no evidence of congestion. The portal vein to caudal vena cava ratio is approximately 1: 1.

The gallbladder is of normal contours and contains some dependent echogenic debris. The wall is normal in thickness. No choleliths are observed. The cystic and common bile ducts are normal/not seen.

**Gastrointestinal**

The gastric lumen is not distended. The gastric wall and pylorus are normal in thickness with a normal layering pattern. The pyloric outflow tract is patent. The small intestinal lumen is not dilated. The small



**PATIENT**

Jagger Gjormand

intestinal wall is normal in thickness with a normal layering pattern and appropriate mural detail. Discreet masses are not identified. The ileoceocolic junction and colonic wall are normal. The colonic lumen contains some shadowing fecal material. There is no obvious evidence of an obstructive pattern.

**SPECIES**

Canine

**Pancreas**

The region of the pancreas is isoechoic relative to surrounding omental fat. No obvious parenchymal abnormalities are observed. There is no evidence of regional inflammation or effusion.

**BREED**

Mini Pinscher

**Lymph Nodes**

The abdominal lymph nodes are normal/not visible.

**SEX**

Neutered Male

**Free Abdomen**

The peritoneal cavity is normal. There is no evidence of inflammation or effusion.

**AGE**

3

**Other**

A brief echocardiogram reveals no evidence of pericardial effusion or obvious right atrial/auricular mass.

**WEIGHT**

Not Provided

**ULTRASONOGRAPHIC FINDINGS**

The hepatic changes are nonspecific and could be secondary to inflammatory disease (i.e., cholangiohepatitis, chronic hepatitis), Leptospirosis, hepatotoxicosis, infiltrative neoplasia (i.e., lymphoma), vacuolar hepatopathy, regenerative nodular hyperplasia, other hepatopathy, or some combination thereof.

**INTERPRETATION OF THE FINDINGS & FURTHER RECOMMENDATIONS**

- Consider pre- and postprandial serum bile acids to assess hepatic function.
- Leptospirosis can be considered. However, given the chronicity of liver enzyme elevations, testing may be of low yield.
- Ultimately, liver biopsies with aerobic and anaerobic bile cultures would likely be necessary to get a definitive diagnosis. If pursued, clotting status is appropriate should be performed prior to anesthesia.
- If a conservative approach is desired, consider empirical treatment for bacterial cholangiohepatitis (amoxicillin-clavulanic acid, Denamarin). If no improvement in the liver values is seen within 7-10 days of initiating therapy, antibiotics should be discontinued, and hepatic tissue sampling reconsidered. If liver values improve, continue therapy for at least 4-6 weeks and 1 week beyond normalization of the liver values.

**INTERPRETED BY**

Andrea Nicastrò DVM  
 Diplomate ACVIM  
 (Sm Animal Internal Med)

**IMAGING PERFORMED BY**

Andrea Nicastrò DVM  
 Diplomate ACVIM  
 (Sm Animal Internal Med)

**HOSPITAL NAME**

Dunes VC

**REFERRING VET**

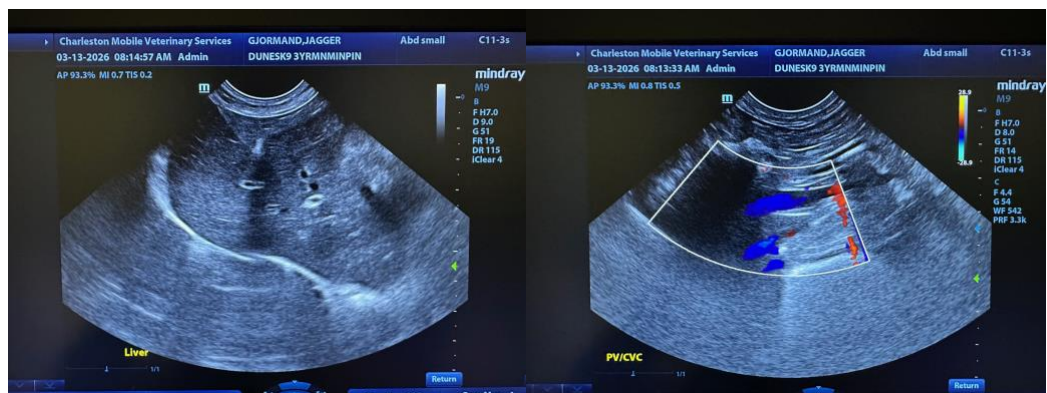
Dr Danny Soileau

**INVOICE**

22680

**DATE**

3-13-26





**PATIENT**

Jagger Gjormand

**SPECIES**

Canine

**BREED**

Mini Pinscher

**SEX**

Neutered Male

**AGE**

3

**WEIGHT**

Not Provided

**INTERPRETED BY**

Andrea Nicastrò DVM  
 Diplomate ACVIM  
 (Sm Animal Internal Med)

**IMAGING PERFORMED BY**

Andrea Nicastrò DVM  
 Diplomate ACVIM  
 (Sm Animal Internal Med)

**HOSPITAL NAME**

Dunes VC

**REFERRING VET**

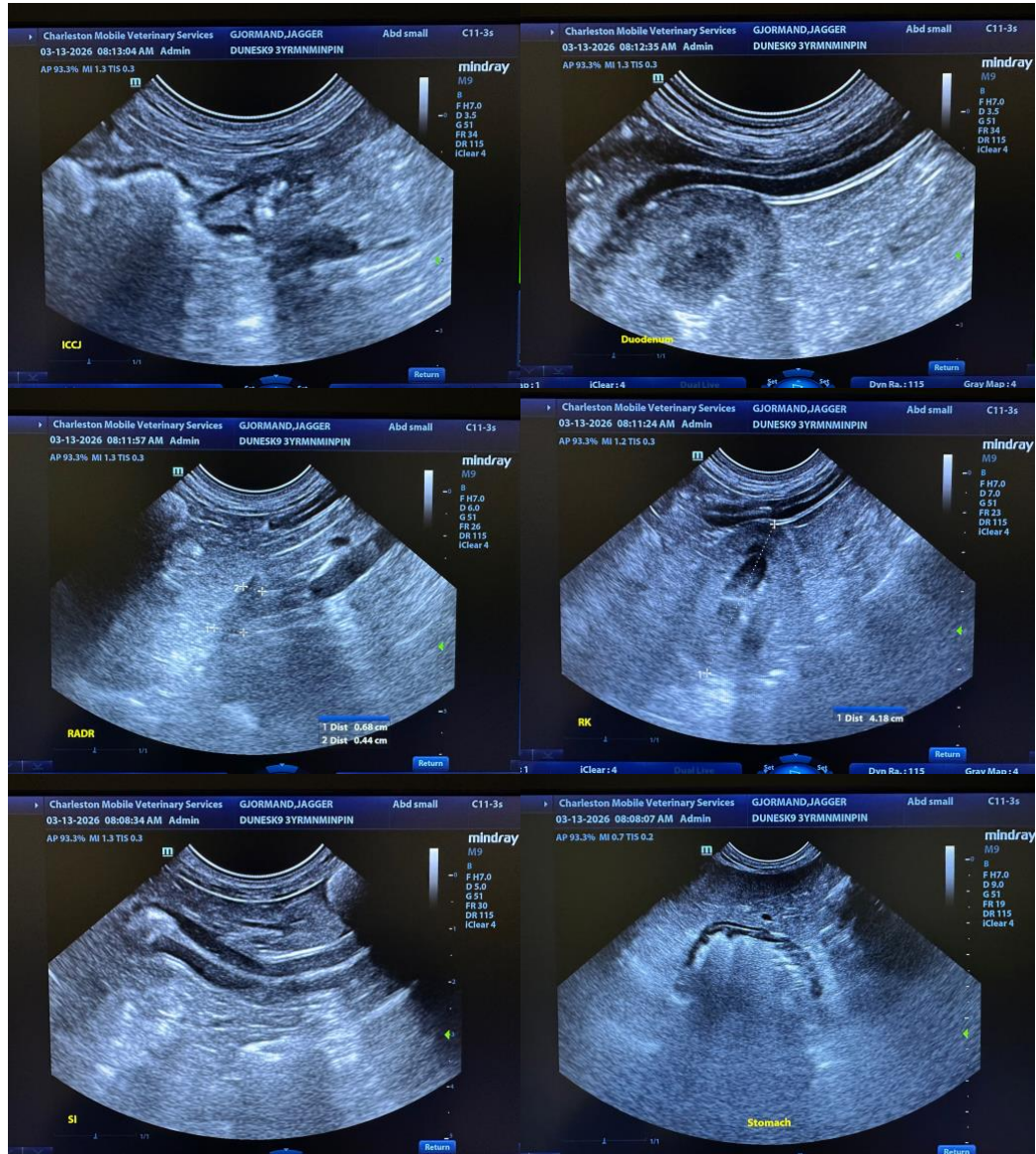
Dr Danny Soileau

**INVOICE**

22680

**DATE**

3-13-26





**PATIENT**

Jagger Gjormand

**SPECIES**

Canine

**BREED**

Mini Pinscher

**SEX**

Neutered Male

**AGE**

3

**WEIGHT**

Not Provided

**INTERPRETED BY**

Andrea Nicastro DVM  
 Diplomate ACVIM  
 (Sm Animal Internal Med)

**IMAGING PERFORMED BY**

Andrea Nicastro DVM  
 Diplomate ACVIM  
 (Sm Animal Internal Med)

**HOSPITAL NAME**

Dunes VC

**REFERRING VET**

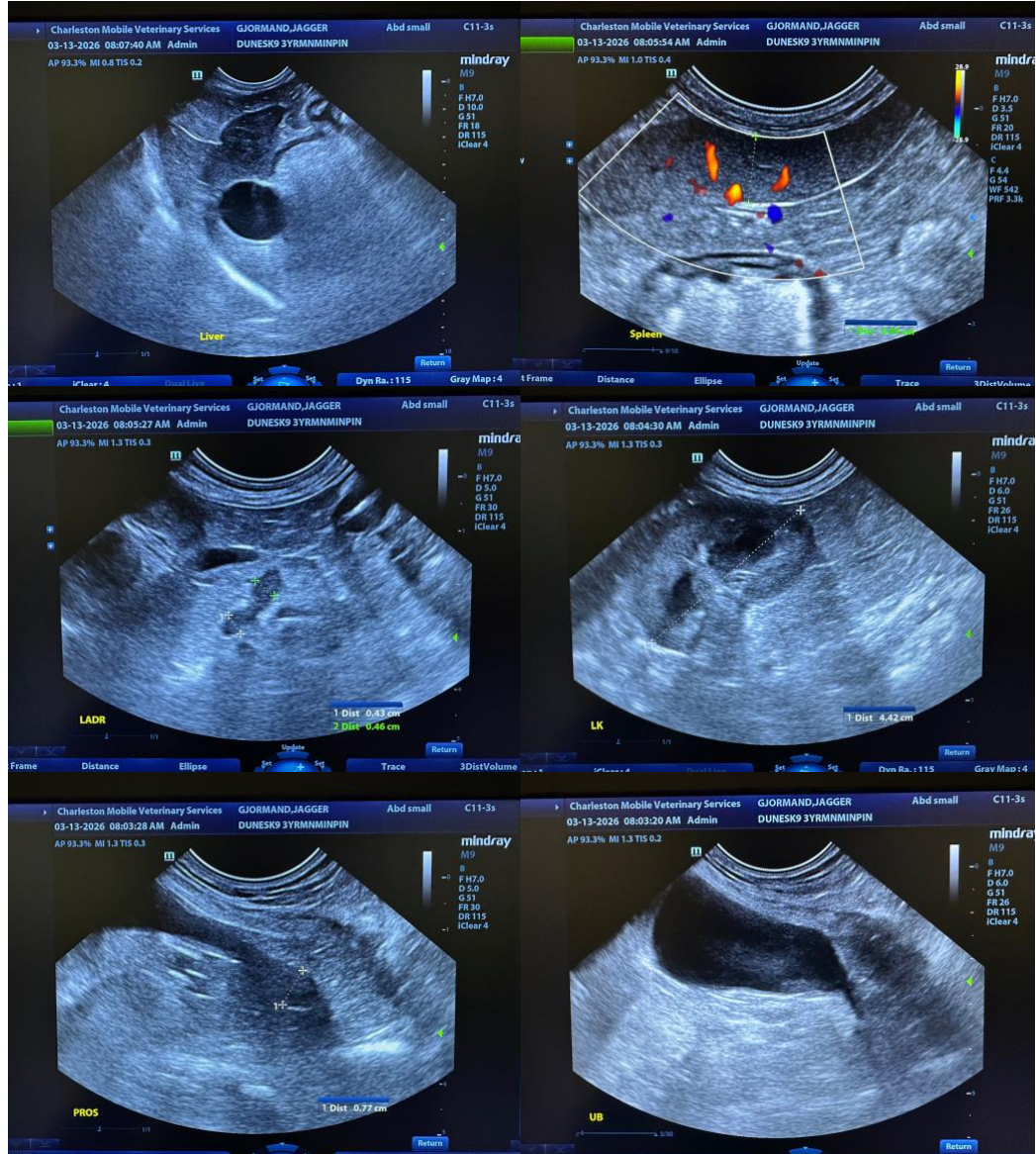
Dr Danny Soileau

**INVOICE**

22680

**DATE**

3-13-26



The information and recommendations provided are based on the images presented by the referring veterinarian/sonographer. No evaluation can be communicated regarding pathology that was not visible in the image/video clips provided.

Thank you for this referral. If the clinical or image interpretation does not parallel your findings or if I can be of any further assistance, please contact me.

**Andrea Nicastro, MPH, DVM, Diplomate DACVIM (Small Animal Internal Medicine)**  
[info@SonoPath.com](mailto:info@SonoPath.com)